

Useful contacts

Hospital	21 043 1000
Department	21 043 3121
Coragem association	21 043 3174
Mutual help group	21 043 3122

Atrial septal defect (ASD)

What is it?

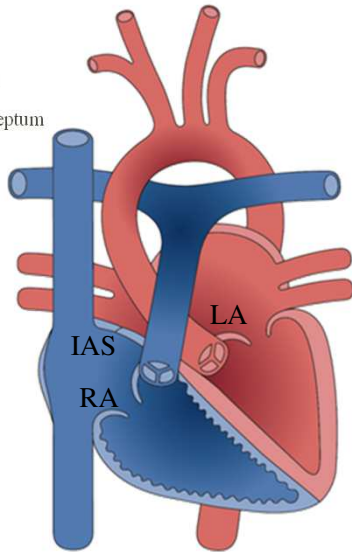
As the name suggests, it is a defect in the interatrial septum – the wall that separates the atria – forming a communication between the two and conditioning a greater flow of blood to the lungs through it. It is one of the most frequent congenital heart diseases and can have several classifications according to its anatomical location.

The cause of this anomaly during the heart's development in fetal life is not fully known, with both genetic or environmental factors being possibly involved.

Normal heart

Caption:

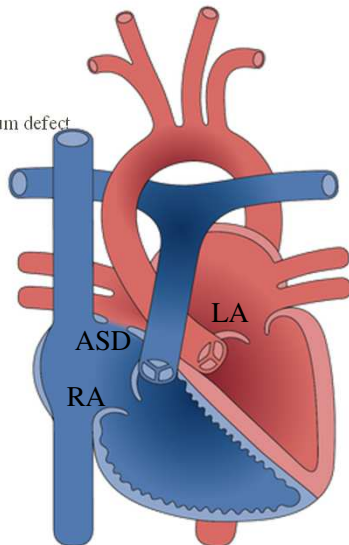
- LA – Left atrium
- RA – Right atrium
- IAS – interatrial septum



Atrial Septal Defect

Caption:

- LA – Left atrium
- RA – Right atrium
- ASD – Atrial septum defect



How is it diagnosed?

The attending physician can detect a heart murmur with or without associated symptoms such as growth disturbance or progressive intolerance to exertion and refer you to a Pediatric Cardiology consultation.

After clinical and echocardiographic evaluation, the diagnosis will be confirmed and a follow-up strategy will be drawn up in order to monitor the disease progression, prevent and identify potential complications and plan the treatment if deemed necessary.

How is it treated?

It is not uncommon to see that a certain type of ASD doesn't have clinical repercussions that justify intervention, and it is perfectly possible to maintain regular surveillance without limitations to everyday life, and furthermore it may even close spontaneously.

Treatment types

In certain cases, a conjunction of signs and symptoms develop progressively that require a therapeutic approach.

Depending on several factors, namely the type of injury, the clinical condition, the age and weight of the patient, the approach considered can be surgical or percutaneous (catheterization).

Other procedures

Other tests may also be necessary to obtain better detailed images and better characterize the lesion, such as a transesophageal echocardiogram (TEE).

This exam is done with sedation and the probe is placed through the mouth to the esophagus, such as an endoscopy, allowing greater proximity to the heart and therefore better detail.

In the future

In most cases the correction is definitive and with no complications and the patient may shortly return to the usual routines without major limitations, whether physical, intellectual or reproductive.

Clinical follow-up

In the short term, the instructions given by the medical and nursing staff at the time of discharge from hospital must be respected, namely medication, limitation of physical activity, removal of stitches, etc.

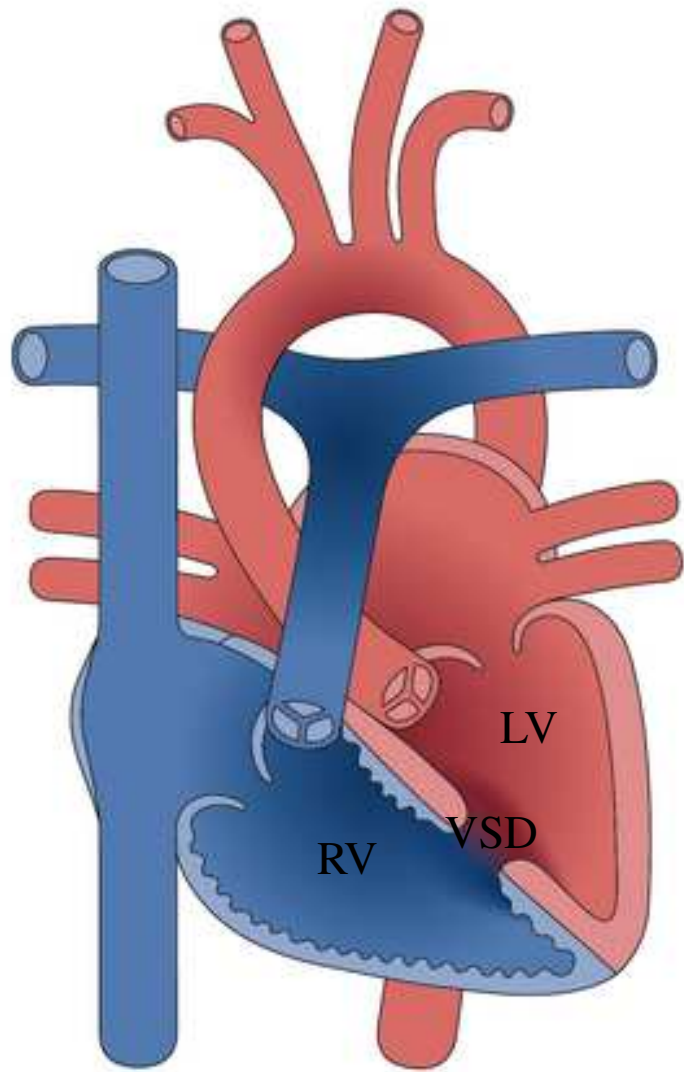
In the medium / long term, a regular follow-up must be maintained but it will be increasingly spaced, according to the plan drawn up by your Pediatric Cardiologist and / or Cardiac Surgeon.

Leaflet prepared by

Dr^a Inês Carmo Mendes
Dr Miguel Fogaça da Mata
Dr^a Maria Ana Esteves
Pediatric Cardiology Department
Hospital de Santa Cruz – CHLO

Acknowledgments

Adapted diagrams of:
<http://www.chd-diagrams.com>.



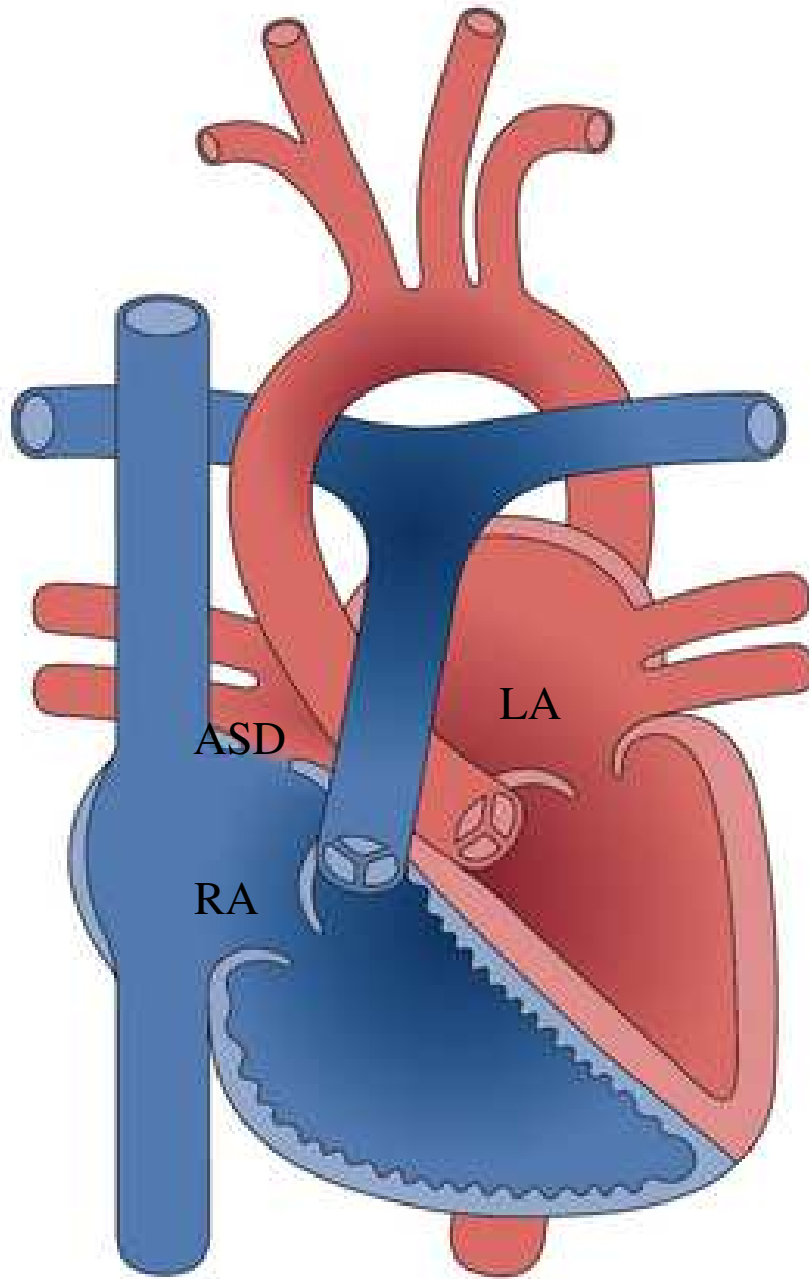
Caption

RV – right ventricle

LV – left ventricle

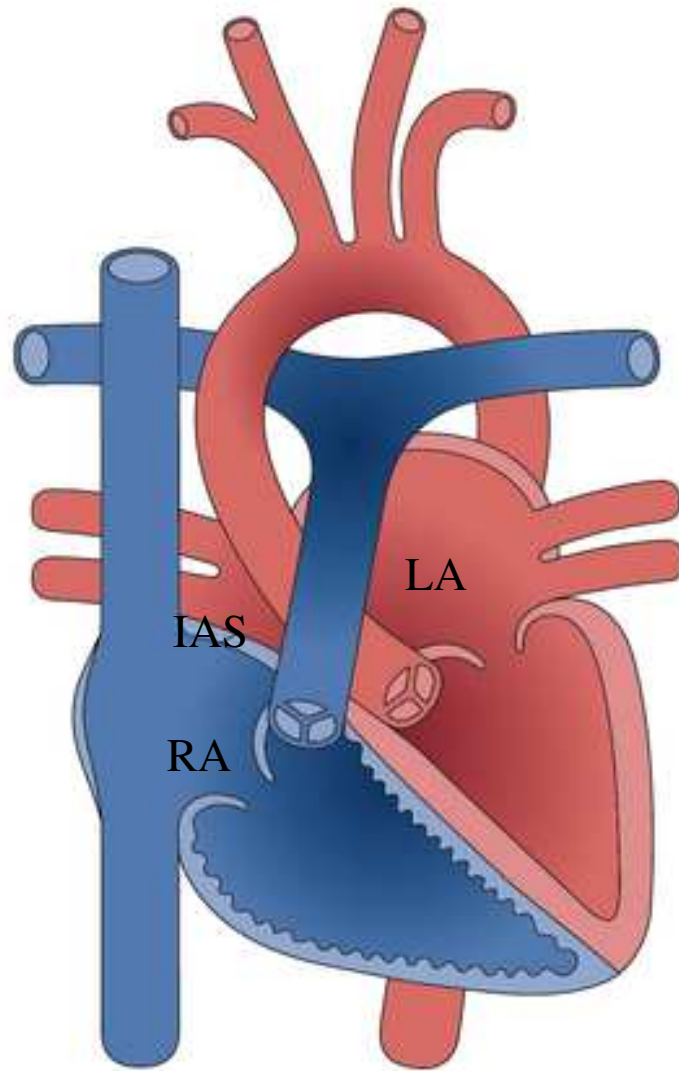
VSD – ventricular septal defect





Caption:
LA – Left atrium
RA – Right atrium
ASD – Atrial septum defect





Caption:

LA – Left atrium

RA – Right atrium

IAS – interatrial septum

Figure 1- Normal heart

